



Review Article

Radiotherapy for pediatric adrenocortical carcinoma – Review of the literature



Verena Wiegering^{a,b,1,*}, Maria Riedmeier^{a,1}, Lester D.R. Thompson^c, Calogero Virgone^d, Antje Redlich^e, Michaela Kuhlen^f, Melis Gultekin^g, Bilgehan Yalcin^h, Boris Decarolisⁱ, Christoph Härtel^{a,b}, Paul-Gerhardt Schlegel^{a,b}, Martin Fassnacht^{b,j}, Beate Timmermann^k

^a University Children's Hospital, Department of Pediatric Hematology, Oncology and Stem Cell Transplantation, University of Wuerzburg, Josef-Schneiderstr. 2, 97080 Wuerzburg, Germany

^b Comprehensive Cancer Centre Mainfranken, University of Wuerzburg Medical Centre, Josef-Schneiderstr. 2, 97080 Wuerzburg, Germany

^c Head and Neck Pathology Consultations, Woodland Hills, CA, USA

^d Pediatric Surgery, Department of Woman's and Child's Health, University Hospital of Padua, Padua, Italy

^e Pediatric Oncology, Otto-von-Guericke-University, Magdeburg, Germany

^f Swabian Children's Cancer Center, University Children's Hospital Augsburg, Augsburg, Germany

^g Department of Radiation Oncology, Hacettepe University, Faculty of Medicine, 06100 Ankara, Turkey

^h Department of Pediatric Oncology, Hacettepe University, Faculty of Medicine, 06100 Ankara, Turkey

ⁱ Department of Pediatric Oncology and Hematology, University Children's Hospital of Cologne, Medical Faculty, Cologne, Germany

^j Department of Medicine, Division of Endocrinology and Diabetes, University Hospital, University of Wuerzburg, Oberduerrbacherstr. 6, 97080 Wuerzburg, Germany

^k Department of Particle Therapy, West German Proton Therapy Centre Essen (WPE), West German Cancer Center (WTZ), Germany, German Cancer Consortium (DKTK), University Hospital Essen, Essen, Germany

ARTICLE INFO

Keywords:

Pediatric adrenocortical cancer
Pediatric adrenocortical carcinoma
Pediatric adrenocortical tumor
Radiotherapy
Therapy
Treatment

ABSTRACT

Background and purpose: Pediatric adrenocortical carcinoma (pACC) is a rare disease with poor prognosis. Publications on radiotherapy (RT) are scarce. This review summarizes the current data on RT for pACC and possibly provides first evidence to justify its use in this setting.

Materials and methods: We searched the PubMed and Embase database for manuscripts regarding RT for pACC. **Results:** We included 17 manuscripts reporting on 76 patients treated with RT, after screening 2961 references and 269 full articles. In addition, we added data of 4 unreported pACC patients treated by co-authors. All reports based on retrospective data. Median age at first diagnosis was 11.1 years (70% female); 78% of patients presented with hormonal activity. RT was mostly performed for curative intent (78%). 88% of RT were administered during primary therapy. The site of RT was predominantly the local tumor bed (76%). Doses of RT ranged from 15 to 62 Gy (median 50 Gy). Information on target volumes or fractionation were lacking. Median follow-up was 6.9 years and 64% of the patients died of disease, with 33% alive without disease. In 16 of 48 patients with available follow-up data after adjuvant RT (33%) no recurrence was reported and in 3 of 9 patients palliative RT seemed to induce some benefit for the patient.

Conclusions: Our first systematic review on RT for pACC provides too few data for any general recommendation, but adjuvant RT in patients with high risk might be considered. International collaborative studies are urgently needed to establish better evidence on the role of RT in this rare malignancy.

Introduction

Pediatric adrenocortical carcinoma (pACC) is a rare malignancy with a poor prognosis and is highly associated with tumor predisposition

syndrome (TPS) [1]. Even after complete surgical resection, about a quarter of all patients may develop local recurrence and/or metastatic disease. Therefore, adjuvant treatment options besides complete surgical resection are urgently needed. Adjuvant treatment with mitotane is

* Corresponding author.

E-mail address: Wiegering_V@ukw.de (V. Wiegering).

¹ Both authors contributed equally.

<https://doi.org/10.1016/j.ctro.2022.05.003>

Received 22 March 2022; Received in revised form 12 May 2022; Accepted 12 May 2022

Available online 14 May 2022

2405-6308/© 2022 Published by Elsevier B.V. on behalf of European Society for Radiotherapy and Oncology. This is an open access article under the CC BY-NC-ND license (<http://creativecommons.org/licenses/by-nc-nd/4.0/>).

often used, but evidence of its efficacy is still lacking, especially in the pediatric context [2,3]. Local recurrence is particularly frequent in pACC, often leading to re-operation [4,5]. Recently, Rodriguez-Galindo, et al., reported in pediatric patients that stage II patients who underwent surgery alone had a more adverse prognosis when compared to stage III patients who received in addition systemic therapy [2]. These findings underscore the necessity of additional treatment in patients with locally advanced tumors.

In the past, radiotherapy (RT) has been sometimes considered an ineffective treatment of ACC [6]. However, several reports with a limited number of adult patients have described tumor response rates up to 42% [7,8]. Although methods and response criteria in these studies do not always fulfill modern standards, these reports show that ACC is not resistant to RT. Furthermore, adjuvant RT in adult ACC patients comes clearly with an improved survival without local recurrence, although it is yet uncertain if overall recurrence-free and overall survival is prolonged [8,9].

In the pediatric setting, evidence for adjuvant RT is even more limited. In a recent systematic review on pACC, we demonstrated that the rate of local recurrences was higher than expected: 81% of reported relapses were due to local recurrences or lymph node metastases [10]. In contrast, local recurrences in the adult setting have been reported only in around 50–60% of patients [11]. This may suggest the possibility of improved patient outcome when introducing a more aggressive local treatment, either with extended surgery and/or consolidating RT. An improvement of overall and disease-free survival due to local RT is known for several pediatric tumors already, such as neuroblastoma patients [12]. Nonetheless, pediatric ACC is highly associated with heritable TP53-related cancer syndromes (about 50–80%) like Li Fraumeni syndrome (LFS) caused by a specific inherited germline mutation at codon 337 in the TP53 suppressor gene [13–16]. The increased lifetime risk of cancer for patients with tumor predisposition syndrome especially after exposure to radio- and/or chemotherapy treatments has to be considered with the determination to implement adjuvant therapy [15]. This systematic review is aimed to summarize the role of RT for pACC and extrapolate possible guidance about its role in this setting.

Methods.

We searched the PubMed and Embase database for manuscripts published between 1st January 1986 and 15th of February 2021. Search terms included: adrenocortical tumor, adrenocortical cancer/

carcinoma, pediatric, paediatric, childhood; using “and” or “or”. All studies with available abstracts in German or English were included. Duplications were automatically removed by the reference manager program (EndNote) as well as being manually checked. Two independent reviewers (MR, VW) performed screening of title and abstracts of all studies. Potentially relevant articles underwent full-text review to determine eligibility for inclusion in our analysis. Inclusion criteria were a minimum of three reported ACC patients younger than 21 years, reporting of clinical, pathologic, and treatment findings. Any disagreement on manuscript inclusion was resolved by consensus. Excerpted data was double-reviewed for inclusion (MR, VW). The search strategy was performed according to Riedmeier et al. [10].

The database search identified 2,961 articles. After removing duplicates, 2,075 remained. After screening by title and abstract, 269 manuscripts were suitable for inclusion. Full-text review of these reports identified 65 manuscripts describing therapy regimes, which were included in our analysis. Of these 65 studies, 17 reported RT. The selection process is visualized in the PRISMA flowchart in Fig. 1. All authors reporting pACC patients treated with RT were contacted to obtain more detailed information regarding RT. Of 17 contacted authors, 6 provided further information on 22 patients who received RT [17–22]. On the remaining 50 patients, no additional information was available. Tumor stages were reported according to the international TNM classification system or the ENSAT criteria [10,23].

Results

The reported literature covered 76 patients treated with RT out of a total cohort of 1,181 reported pACC patients. Available information on RT from the literature is listed in Table 1. None of these were randomized controlled trials (RCTs) but retrospective analyses, with 76 patients managed with RT [10]. Additionally, we included data of 4 previous unreported patients upon receiving further information from the authors. Of these 80 patients, intention of RT was described for 41 patients. It was performed for curative intent in 32 (78%) and palliation in 9 (22%). The site of RT was described in 37 patients: tumor bed (76%), abdominal cavity (16%), and/or metastases (19%) (7 patients: bone = 3; pulmonary = 2; CNS = 1; axilla = 1), respectively. Reported doses of RT ranged from 15 Gy to 62 Gy (median 50 Gy). In most of the reported patients, no information on target volumes or fractionation were

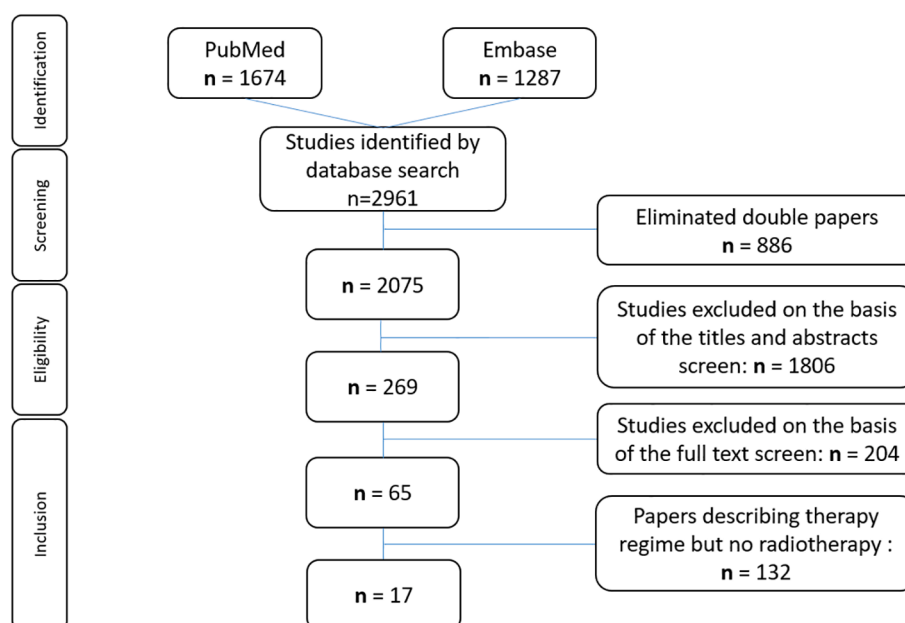


Fig. 1. Search criteria Flow diagram of the search strategy and evidence acquisition in a systematic review on Radiotherapy in Pediatric Adrenocortical Carcinoma.

Table 1
Data of radiotherapy of pediatric patients with adrenocortical tumor of selected original publications identified by systematic literature review.

Authors	All patients	Patients with RT (n)	Patient number	Age (years)	Sex	Hormone production	Tested for p53mutation	Tumor stage	Curative/palliative	Tumor fields	Total dose (Gy)	RT technique	Fraction dose	Surgery (yes/no)	Chemotherapy (yes/no)	Mitotane (yes/no)	Reason of RT	Follow-up (in years)	Patient outcome	
Bergada I, 1996 [24]	20	1 (reported*)	1	11.5	F	Cushing	n/a	n/a	Curative	Tumor bed	n/a	n/a	n/a	Yes, R1 With Extracapsular Invasion	Yes, 6 cycles	No	Primary therapy, Extracapsular invasion	8,5	Alive	
Gultekin & Yalcin, 2021 (Hacettepe Series) [22]	33	4 (3 not reported, additional information to all patients received from the author*)	1 (not reported)	17	F	Mixed	n/a	2	Curative	Tumor bed	50	IMRT	2 Gy	Yes; R0	No	Yes	Primary therapy, Locally tumor extension	7,5	Alive, CR	
			2 (not reported)	13	M	Virilization	n/a	3	Curative	Right surrenal bed and PA region	54 (50.4 + 3.6)	IMRT	1.8 Gy	Yes; R1	Yes, 6 cycles	Yes	Primary therapy, Locally tumor extension	3,8	Alive, CR	
			3 (not reported)	9	M	Mixed	n/a	4	Curative	Tumor bed	45	IMRT	2 Gy	Yes; R1	Yes	Yes	Relapse	2,7	DOD	
			4 (reported in 2011)	14.3	M	n/a	n/a	n/a	Curative	Tumor bed	45	IMRT	1.8 Gy	Yes; R2	Yes	Yes	Primary therapy, Locally tumor extension	1,5	DOD	
Dall'Igna P, 2014 [18]	58	3 (1 not reported, additional information to all patients received from the author *)	1	1.1	F	Virilization	Tested, n/a	1	Curative	Tumor bed	n/a	60 Co-teletherapy (TCT)	n/a	Yes; R0	Yes, vincristine	No	primary therapy	10	Alive, CR	
			2	7.8	M	Virilization	Positive tested	2	Curative	Lung metastases	n/a	stereotactic radiosurgery	n/a	Yes, surgery on primary tumor, lung and liver metastases	Yes	Yes	Relapse, pulmonary metastasis	9,8	DOD	
			3	8	M	Non functional	Tested, n/a	4	Curative	Primary tumor	n/a	60 Co-teletherapy (TCT)	n/a	Yes, biopsy only	Yes	Yes	Primary therapy, only biopsy	1,1	DOD	
Driver CP, 1998 [25]	14	12 (all reported*)	1–3	n/a	n/a	n/a	n/a	n/a	n/a	n/a	n/a	n/a	n/a	n/a	n/a	Primary therapy	n/a	n/a		
Gupta N, 2018 [26]	41	4 (all reported*)	1	>12	n/a	n/a	Not tested	4	Palliative	n/a	n/a	n/a	n/a	n/a	No, inoperable	Yes	n/a	Primary therapy, inoperable tumor	<8 mo	DOD
			2	>12	n/a	n/a	Not tested	4	Palliative	n/a	n/a	n/a	n/a	n/a	No, inoperable	Yes	n/a	Primary therapy, inoperable tumor	<8 mo	DOD
			3	>12	n/a	n/a	Not tested	n/a	n/a	n/a	n/a	n/a	n/a	n/a	n/a	n/a	n/a	Primary therapy	n/a	n/a
			4	>12	n/a	n/a	Not tested	n/a	n/a	n/a	n/a	n/a	n/a	n/a	n/a	n/a	n/a	Primary therapy	n/a	n/a
Hanna AM, 2008 [27]	23	2 (all reported*)	1	n/a	n/a	n/a	4	Palliative	Tumor bed	n/a	n/a	n/a	n/a	No	Yes, neoadjuvant	No	Primary therapy, inoperable tumor	n/a	n/a	
Klein JD, 2011 [28]	29	3 (all reported*)	1	n/a	n/a	n/a	2?	Curative	Tumor bed	n/a	n/a	n/a	n/a	Yes, locally advanced stageblock resection	Yes	No	Primary therapy, locally tumor extension	n/a	relapse, DOD	
			2	n/a	n/a	n/a	2?	Curative	Tumor bed	n/a	n/a	n/a	n/a	Yes, locally advanced	Yes	No	Primary therapy,	n/a	relapse, DOD	

(continued on next page)

Table 1 (continued)

Authors	All patients	Patients with RT (n)	Patient number	Age (years)	Sex	Hormone production	Tested for p53mutation	Tumor stage	Curative/palliative	Tumor fields	Total dose (Gy)	RT technique	Fraction dose	Surgery (yes/no)	Chemotherapy (yes/no)	Mitotane (yes/no)	Reason of RT	Follow-up (in years)	Patient outcome
			3	n/a	n/a	n/a	Tested, n/a	n/a	Curative	Tumor bed	n/a	n/a	n/a	stageblock resection Yes, R1 and Cava infiltration	No	No	locally tumor extension	>12	2nd malignancy, death of chondrosarcoma
Knopfle G, 1986 [29]	2	1 (reported*)	1	11	F	Cushing	n/a	2/3	Curative	Tumor bed	40.5	n/a	n/a	Yes, R0	Yes	No	Primary therapy, close proximity to VCI	2	DOD after 2 years
	150	16 (all reported*)	1–16	n/a	n/a	n/a	n/a	3/4	n/a	n/a	15–50	n/a	n/a	n/a	n/a	n/a	Primary therapy, locally tumor extension	n/a	12 patients DOD, 4 patient alive (all aged at diagnosis < 7 years)
McAteer JP, 2013 [30]	85	8 (all reported*)	1–8	5–9 (1); 10–14 (2); 15–19 (5)	n/a	n/a	n/a	n/a	n/a	n/a	n/a	n/a	n/a	n/a	n/a	n/a	Primary therapy: adjuvant or palliative care	37,5% 5 yr OS	n/a
Michalkiewicz E, 2004 [1]	254	2 (all reported*)	1	n/a	n/a	n/a	n/a	2	Curative	Tumor bed	n/a	n/a	n/a	n/a	n/a	n/a	Primary therapy, locally tumor extension	n/a	n/a
			2	n/a	n/a	n/a	n/a	n/a	Curative	Tumor bed	n/a	n/a	n/a	n/a	n/a	n/a	Primary therapy, locally tumor extension	n/a	n/a
Patil KK, 2002 [31]	21	1 (reported*)	1	n/a	n/a	n/a	n/a	n/a	n/a	Tumor bed	n/a	n/a	n/a	Yes	Yes	n/a	n/a	n/a	DOD after 6 m
Picard C, 2019 [32]**	95	1 (reported*)	1	n/a	n/a	n/a	n/a	n/a	Palliative	n/a	n/a	n/a	n/a	n/a	n/a	n/a	n/a	n/a	n/a
Picard C, 2020 [33]**	95	1(2?) (reported*)	1	n/a	n/a	n/a	n/a	n/a	Palliative	n/a	n/a	n/a	n/a	n/a	n/a	n/a	n/a	n/a	n/a
Redlich A, 2012 [19]	60	7 (all reported and additional information received from the author*)	1	8.3	F	Non functional	n/a	4	Curative	CNS	40–56 (mean 45)	n/a	n/a	n/a	n/a	n/a	Primary therapy, brain metastases	11,2	n/a
			2	2.2	M	Yes	n/a	3	Curative	Tumor bed	40–56 (mean 45)	n/a	n/a	Yes	No	Yes	Relapse, local and lung metastases	7,0	Alive
			3	17.1	F	Yes	n/a	3	Curative	Tumor bed	40–56 (mean 45)	n/a	5w	Yes	No	No	Primary therapy	8,0	Alive
			4	8.4	F	Yes	n/a	2	Palliative	Tumor bed, secondary abd. Cavity	45	n/a	n/a	Yes	No	No	Relapse, local and metastases	1,7	DOD
			5	15.5	F	Non functional	n/a	4	Curative	Tumor bed	40–56 (mean 45)	n/a	5w	Yes, R1	Yes, cisplatin	Yes	Primary therapy	4,6	Alive
			6	8.8	F	Yes	n/a	4	Curative		454,515	n/a	n/a	Yes	No	No	Primary therapy	2,9	Alive

(continued on next page)

Table 1 (continued)

Authors	All patients	Patients with RT (n)	Patient number	Age (years)	Sex	Hormone production	Tested for p53mutation	Tumor stage	Curative/palliative	Tumor fields	Total dose (Gy)	RT technique	Fraction dose	Surgery (yes/no)	Chemotherapy (yes/no)	Mitotane (yes/no)	Reason of RT	Follow-up (in years)	Patient outcome
			7	11.3	F	Yes	n/a	2	Curative	Left axilla; tumor bed; lung	40–56 (mean 45)	n/a	n/a	Yes, R1	No	No	Relapse, local	2,1	DOD
Tucci S Jr, 2005 [21]	34	3 (all reported, no additional information available from the author*)	1	n/a	n/a	n/a	n/a	n/a	Palliative	Bone metastasis	25–40	n/a	2-4w	n/a	n/a	n/a	Pain control	n/a	DOD, good pain control
			2	n/a	n/a	n/a	n/a	n/a	Palliative	Bone metastasis	25–40	n/a	2-4w	n/a	n/a	n/a	Pain control	n/a	DOD, good pain control
			3	n/a	n/a	n/a	n/a	n/a	Palliative	Bone metastasis	25–40	n/a	2-4w	n/a	n/a	n/a	Pain control	n/a	DOD, good pain control
Wieneke JA, 2003 [17]	83	8 (all reported and additional information received from the author*)	1	15	F	Cushing	Tested, n/a	2	Curative	Tumor bed	n/a	n/a	n/a	Yes	No	No	Primary therapy, locally tumor extension	28	Alive
			2	15	F	Virilization	Tested, n/a	2	Curative	Tumor bed	62	n/a	n/a	Yes	Yes	No	Primary therapy	2,5	DOD, lymph node/Peritoneum
			3	5	F	Non functional	Tested, n/a	3	Curative	Tumor bed	30	n/a	n/a	Yes	Yes	No	Primary therapy, locally tumor extension	1,4	DOD, pulmonary metastasis
			4	16	M	Cushing	Tested, n/a	3	Curative	Tumor bed	45	n/a	n/a	Yes	Yes	No	Primary therapy, locally tumor extension	1,9	DOD, pulmonary metastasis
			5	15	F	Non functional	Tested, n/a	3	Curative	Abd. Cavity	22 to abd. cavity	n/a	n/a	Yes	No	No	Primary therapy	20	alive
			6	10	F	Virilization	Tested, n/a	2	Curative	Tumor bed	55	n/a	n/a	Yes	Yes	No	Primary therapy	8	alive
			7	1.4	F	Mixed	Tested, n/a	2	Curative	Abd. Cavity	24 to abd. cavity	n/a	n/a	Yes	No	No	Primary therapy	19	alive
			8	16	F	Virilization	Tested, n/a	2	Curative	Abd. Cavity	41 to abd. cavity	n/a	n/a	Yes	Yes	No	Primary therapy	10	DOD, retroperitoneal
Zerbini C, 1992 [20]	35	1 (reported, no additional information available from the author*)	1	n/a	n/a	n/a	Tested, n/a	n/a	Curative	n/a	n/a	n/a	n/a	Yes	No	No	Primary therapy	n/a	n/a
Evanoff J, 2021 [34]	49	2 (all reported*)	1–2	n/a	n/a	n/a	n/a	2	Curative	Tumor bed	n/a	n/a	n/a	Yes	n/a	n/a	n/a	n/a	n/a
total	1181	76 (reported*) + 4 (not reported*)																	

Summary of data of radiotherapy of 67 reported patients plus 4 in literature not reported patients out of a collective of 1181 reported and 26 not reported patients.

* not reported patients = previous in literature unreported patients upon receiving further information from the authors.

** presumable description of the same patient.

Abbreviations: RT = radiotherapy, n/a = not available, CR = complete remission, DOD = date of death, M = male, F = female, IMRT = intensity-modulated radiotherapy, TCT = 60 Co-teletherapy, mo = months, w = weeks, OS = overall survival, CNS = central nervous system, abd. = abdominal, VCI = vena cava inferior.

available. Of the patients who received RT, 91% also had surgery (19% >R0), 55% received chemotherapy, with overall 27% receiving mitotane (see Table 1).

In 40 patients, the timing of RT was reported, with 35 patients (88%) receiving RT during primary therapy. Therefore, the most common reasons to apply RT were inoperability, incomplete resection and/or the control of local tumor recurrence in patient with high risk features. Of the five patients who received RT for relapse, two patients received radiation for both the tumor bed and metastasis due to local and distant recurrence.

With regard to patient characteristics, patients' median age was 11.1 years, ranging from 1.1 to 17.1 years. The majority (70%) of patients were female and 78% had hormone-producing tumors with virilization (46%), Cushing syndrome (31%), and mixed hormone production (23%). The majority of patients receiving RT as local control of the disease was stage 2 (45%; 14/31). However, RT was also administered for patients with stage 4 (32%; 10/31), stage 3 (25%, 8/31), or stage 1 (3%; 1/31) disease, respectively. Follow up data was reported for 48 of 80 patients, ranging from < 8 to > 144 months. Notably, in 16 of 48 patients (33%) no recurrence was reported after adjuvant RT at last follow up ranging from 2.9 to 28 years. After incomplete resection followed by adjuvant RT, one out of 7 patients remained free of disease at last follow up 3.8 years after primary therapy. 31 patients (64%) had died of disease, and 2 patients were alive with recurrence and one patient died of a second malignancy. With regard to palliative care, 3 of the 9 patients benefited from palliative RT in terms of improved pain control.

We could not identify any information on relevant short-term or long-term adverse events as a result of RT based on reported data. Furthermore, there is a lack of reliable information in the literature about testing or detection of gene mutations as PT53 gene mutation in pACC that received RT.

Discussion

In the adult setting there is considerable evidence of the efficacy of RT for local control after radical resection, but also in advanced disease. Therefore, current guidelines suggest RT for certain subgroups of patients (e.g. R1 resection) [35,36]. In order to investigate any parallels for pediatric patients, we conducted a systematic literature review. In light of the comparatively high rate of recurrence of pACC—in particular local recurrence—an improvement in local therapy is urgently needed. In the past, RT has often been considered relatively contraindicated for treatment of pACC due to possible long-term side effects of RT and the known association of pACC with tumor predisposition syndromes (TPS)—especially in young childhood where the potential long-term risk from RT would be significant over the patient's lifetime.

As with any intervention, the oncological benefit needs to be carefully weighed against the potential toxicity of the treatment. In order to aid patients and clinicians in the medical decision-making, we aimed to investigate the circumstances and outcomes of reported pACC patients managed with RT.

The use of adjuvant RT in (adult) ACC has clearly grown particularly since 2006, as several publications demonstrated high efficacy reporting local control rates ranging from 56% to 100% [8,9,37,38].

However, within the pediatric setting there are surprisingly few reports. In part, this may be explained by the supposed high incidence of heritable TP53-related cancer syndromes, as well as by the lack of systematic international registries and therapy protocols for these patients. Further, in the pediatric cohort, RT was only given in cases with particularly high risk for local failure, which suggests a bias of reported patients. Therefore, in order to gain clear evidence on the efficacy of RT patients have to be enrolled in randomized controlled trials (RCTs) or at least in standardized prospective registry trials enabling research. Still, recently published pediatric data [2,10] showed improvements in local control and long-term outcomes in pACC patients managed with RT.

Riedmeier et al., showed 81% of relapsed patients presenting with a local recurrence or lymph node metastases [10]. This rate is considerably higher than previously reported in adult setting (50–60%) [11]. Recent data (in adult cohorts) demonstrated that primary lymphadenectomy [39,40], as well as the oncological experience in adrenal cortical tumors (ACT) [41], had an impact on outcome. In our analysis, most surgeries in children with ACC have been performed by pediatric surgeons in centers with limited experience in ACT surgery as indicated by the low patient numbers in a given time frame [2,42]. A step towards therapy optimization may be the systematic retrospective and prospective analysis of the surgical procedures performed regarding lymphadenectomy, relapse rates, and surgical experience in order to define subgroups with an increased risk of relapse and to identify the patients who would benefit from these approaches. The ARAR0332 trial attempted to address this issue, but found no survival benefit. However, the number of removed lymph nodes was generally low. Thus, for this specific pACC patient cohort, we advocate centralization of surgical procedures, which is beneficial in the vast majority of oncological surgical procedures [43–46], particularly when tumors are rare.

In addition to the surgical approach, the possible impact of RT on local recurrence has to be evaluated further in pediatric patients. In the adult setting, adjuvant tumor bed irradiation has been shown to be effective in reducing the high rate of local recurrence in ACC [9,47]. Effects on improving overall and relapse-free survival have been suggested but are still debated [8,36,38]. In the pediatric setting, improvement of overall and disease-free survival due to local RT is known for several tumors, including neuroblastoma, which develops in a similar location [12]. However, at present, the data regarding RT in pACC is too limited to give any general recommendation. When RT is employed, it seems feasible and safe, although we have to acknowledge that adverse effects were not systematically described. However, there was no report on the development of a secondary malignancy in this setting. Interestingly, even in patients with incomplete resection, at least one patient remained disease free. Given the overall poor survival for stage II patients, the findings from the ARAR0332 trial and the positive impact of adjuvant RT on local control in adult patients, suggest consideration for resection followed by adjuvant RT in pACC patients with positive margins or high-risk features.

Published literature has demonstrated a high association between pACC and heritable TP53 related cancer syndromes—like Li Fraumeni syndrome (LFS). Up to 81% of patients, specifically in Southern Brazil carry germline TP53 variants, mainly due to the common germline TP53 mutation R337H [10,15,48]. Because patients with tumor predisposition syndrome carriers have a high lifetime risk of developing multiple primary malignancies, particularly after exposure to radio- and/or chemotherapy treatments [49], determination to implement RT must be weighed critically against risk factors and toxicity [15,50]. One of the largest retrospective studies by Bougeard, et al., on LFS patients reported the incidence of secondary tumors in a previous radiation field at 30% [16]. In the report from Hendrickson, et al., on patients with LFS receiving RT, there was no statistically significant difference between the RT and non-RT group with respect to the development of a subsequent malignancy despite poorer survival outcomes among the RT group [51]. However, from other cancer types associated with LFS, negative effects of RT on survival have been described. From a systematic review, 28 patients with choroid plexus tumors and LFS were identified. Statistical analysis revealed that the survival of patients receiving radiation was inferior to patients without radiation [52]. However, as there is a positive impact of adjuvant RT on local control and survival, TPS may represent a retained relative but not an absolute contraindication for ACC patients and may be considered individually, especially for patients with high-risk features and high tumor stage.

When extrapolating adult data to pediatric treatment strategies, it must be taken into consideration that the tumors are not equivalent. Grisanti, et al., recently compared treatment regimens [53]. Historically, treatment of pACC has been borrowed from adult ACC and with

significant overlap.

By analyzing age-dependent influence on clinical characteristics and outcome of pediatric patients, we confirmed that pACC in patients < 4 years have biologically distinct features that distinguish it from older children and adults [10,54,55]. These differences appear to be more significant than the differences between pre- and post-pubertal patients. Presumably, the tumor pathogenesis of older children and adults have more similarities. The frequency of germline TP53 mutation also decreases with age, while this rate is 58% in cases under the age of 12, it decreases to 25% in cases aged 12–20 years [48]. Ginsburg, et al., suggested that adult patients with high risk for recurrence showed an improved overall survival when treated with adjuvant RT. Even though evidence of RT in pediatric ACC is too limited to make general recommendations, these results warrant further evaluation in trying to maximize survival [38].

In an effort to maximize survival in pediatric patients with high-risk ACC, adjuvant RT has to be discussed—even in the context of TPSs—at least for patients with risk factors such as positive surgical margins, high grade disease, or large tumors (>6 cm). Previous studies have limitations: none were systematic studies; none had standardized indications for RT; there were no information available about specific RT sites or dosage. RT seemed to be well tolerated and possibly contributed to improved survival. Thus, cooperative groups as established within the European Cooperative Study Group for Pediatric Rare Tumors (EXPERT) could be the platform for common randomized trials to further improve patient outcomes in pediatric patients [56,57]. Furthermore, the ENSAT consortium [58,59], which mainly covers adult ACT patients, has shown how centralization and networking can continuously improve patient outcomes, particularly in rare cancer entities. Therefore, it is advisable to encourage a collaboration between the existing groups dedicated to pediatric and adults ACC, aiming for a synergistic action to bring more evidence in the treatment of pACC patients and to improve prognosis and treatment, including a systematic international registry and a common research platform finally leading also to more prospective clinical trials in adolescents.

Declaration of Competing Interest

The authors declare that they have no known competing financial interests or personal relationships that could have appeared to influence the work reported in this paper.

References

- Michalkiewicz E, Sandrini R, Figueiredo B, Miranda ECM, Caran E, Oliveira-Filho AG, et al. Clinical and outcome characteristics of children with adrenocortical tumors: a report from the International Pediatric Adrenocortical Tumor Registry. *J Clin Oncol* 2004;22(5):838–45.
- Rodriguez-Galindo C, Krailo MD, Pinto EM, Pashankar F, Weldon CB, Huang LI, et al. Treatment of Pediatric Adrenocortical Carcinoma With Surgery, Retroperitoneal Lymph Node Dissection, and Chemotherapy: The Children's Oncology Group ARAR0332 Protocol. *J Clin Oncol* 2021;39(22):2463–73.
- Abib SCV, Weldon CB. Management of Adrenal Tumors in Pediatric Patients. *Surg Oncol Clin N Am* 2021;30(2):275–90.
- Fassnacht M, Kroiss M, Allolio B. Update in adrenocortical carcinoma. *J Clin Endocrinol Metab* 2013;98(12):4551–64.
- Megerle F, Kroiss M, Hahner S, Fassnacht M. Advanced Adrenocortical Carcinoma – What to do when First-Line Therapy Fails? *Exp Clin Endocrinol Diabetes* 2019;127(02/03):109–16.
- Luton J-P, Cerdas S, Billaud L, Thomas G, Guilhaume B, Bertagna X, et al. Clinical features of adrenocortical carcinoma, prognostic factors, and the effect of mitotane therapy. *N Engl J Med* 1990;322(17):1195–201.
- Fassnacht M, Hahner S, Polat B, Koschker A-C, Kenn W, Flentje M, et al. Efficacy of adjuvant radiotherapy of the tumor bed on local recurrence of adrenocortical carcinoma. *J Clin Endocrinol Metab* 2006;91(11):4501–4.
- Zhu J, Zheng Z, Shen J, Lian X, Miao Z, Shen J, et al. Efficacy of adjuvant radiotherapy for treatment of adrenocortical carcinoma: a retrospective study and an updated meta-analysis. *Radiat Oncol* 2020;15(1).
- Viani GA, Viana BS. Adjuvant radiotherapy after surgical resection for adrenocortical carcinoma: A systematic review of observational studies and meta-analysis. *J Cancer Res Ther* 2019;15(Supplement):S20–6.

- Riedmeier M, Decarolis B, Haubitz I, Müller S, Uttinger K, Börner K, et al. Adrenocortical Carcinoma in Childhood: A Systematic Review. *Cancers (Basel)* 2021;13(21):5266.
- Erdogan I, Deuschbein T, Jurowich C, Kroiss M, Ronchi C, Quinkler M, et al. The role of surgery in the management of recurrent adrenocortical carcinoma. *J Clin Endocrinol Metab* 2013;98(1):181–91.
- Jazmati D, et al. Proton Beam Therapy for Children With Neuroblastoma: Experiences From the Prospective KiProReg Registry. *Front Oncol* 2020;10:617506.
- Ribeiro RC, Sandrini F, Figueiredo B, Zambetti GP, Michalkiewicz E, Lafferty AR, et al. An inherited p53 mutation that contributes in a tissue-specific manner to pediatric adrenal cortical carcinoma. *Proc Natl Acad Sci USA* 2001;98(16):9330–5.
- Pinto EM, Billerbeck AEC, Villares MCBF, Domesice S, Mendonça BB, Latronico AC. Founder effect for the highly prevalent R337H mutation of tumor suppressor p53 in Brazilian patients with adrenocortical tumors. *Arq Bras Endocrinol Metabol* 2004;48(5):647–50.
- Frebourg T, Bajalica Lagercrantz S, Oliveira C, Magenheimer R, Evans DG. Guidelines for the Li-Fraumeni and heritable TP53-related cancer syndromes. *Eur J Hum Genet* 2020;28(10):1379–86.
- Bougeard G, Renaux-Petel M, Flaman J-M, Charbonnier C, Fermeijer P, Belotti M, et al. Revisiting Li-Fraumeni Syndrome from TP53 Mutation Carriers. *J Clin Oncol* 2015;33(21):2345–52.
- Wieneke JA, Thompson LD, Heffess CS. Adrenal cortical neoplasms in the pediatric population: a clinicopathologic and immunophenotypic analysis of 83 patients. *Am J Surg Pathol* 2003;27(7):867–81.
- Dall'Igna P, Virgone C, De Salvo GL, Bertorelle R, Indolfi P, De Paoli A, et al. Adrenocortical tumors in Italian children: analysis of clinical characteristics and P53 status. Data from the national registries. *J Pediatr Surg* 2014;49(9):1367–71.
- Redlich A, Boxberger N, Strugala D, Frühwald M, Leuschner I, Krof S, et al. Systemic treatment of adrenocortical carcinoma in children: Data from the German GPOH-MET 97 trial. *Klin Padiatr* 2012;224(06):366–71.
- Zerbini C, Kozakewich HPW, Weinberg DS, Mundt DJ, Edwards JA, Lack EE. Adrenocortical neoplasms in childhood and adolescence: Analysis of prognostic factors including DNA content. *Endocr Pathol* 1992;3(3):116–28.
- Tucci Jr S, et al. The impact of tumor stage on prognosis in children with adrenocortical carcinoma. *J Urol* 2005;174(6):2338–42. discussion 2342.
- Buyukpamukcu M, et al. Adrenocortical carcinomas in children: Hacettepe experience. *Pediatr Blood Cancer* 2011;57(5):802.
- Fassnacht M, Johansen S, Quinkler M, Bucsky P, Willenberg HS, Beuschlein F, et al. Limited prognostic value of the 2004 International Union Against Cancer staging classification for adrenocortical carcinoma: proposal for a Revised TNM Classification. *Cancer* 2009;115(2):243–50.
- Bergadá I, Venara M, Maglio S, Ciaccio M, Diez B, Bergadá C, et al. Functional adrenal cortical tumors in pediatric patients: A clinicopathologic and immunohistochemical study of a long term follow-up series. *Cancer* 1996;77(4):771–7.
- Driver CP, Birch J, Bruce J. Adrenal cortical tumors in childhood. *Pediatr Hematol Oncol* 1998;15(6):527–32.
- Gupta N, Rivera M, Novotny P, Rodriguez V, Bancos I, Lteif A. Adrenocortical Carcinoma in Children: A Clinicopathological Analysis of 41 Patients at the Mayo Clinic from 1950 to 2017. *Horm Res Paediatr* 2018;90(1):8–18.
- Hanna AM, Pham TH, Askegard-Giesmann JR, Grams JM, Iqbal CW, Stavlo P, et al. Outcome of adrenocortical tumors in children. *J Pediatr Surg* 2008;43(5):843–9.
- Klein JD, Turner CG, Gray FL, Yu DC, Kozakewich HP, Perez-Atayde AR, et al. Adrenal cortical tumors in children: factors associated with poor outcome. *J Pediatr Surg* 2011;46(6):1201–7.
- Knopfle G, Fodisch HJ, Holschneider A. Adrenal cortical carcinoma in childhood and adolescence. *Klin Padiatr* 1986;198(3):250–6.
- McAteer JP, Huaco JA, Gow KW. Predictors of survival in pediatric adrenocortical carcinoma: A Surveillance, Epidemiology, and End Results (SEER) program study. *J Pediatr Surg* 2013;48(5):1025–31.
- Patil KK, Ransley PG, McCullagh M, Malone M, Spitz L. Functioning adrenocortical neoplasms in children. *BJU Int* 2002;89(6):562–5.
- Picard C, Orbach D, Carton M, Brugières L, Renaudin K, Aubert S, et al. Revisiting the role of the pathological grading in pediatric adrenal cortical tumors: results from a national cohort study with pathological review. *Mod Pathol* 2019;32(4):546–59.
- Picard C, Faure-Contier C, Leblond P, Brugières L, Thomas-Teinturier C, Hameury F, et al. Exploring heterogeneity of adrenal cortical tumors in children: The French pediatric rare tumor group (Fracture) experience. *Pediatr Blood Cancer* 2020;67(2).
- Evanoff JD, Patel SG, Hickey KJ, Rensing AJ. Survival characteristics of localized pediatric adrenocortical carcinoma managed with adrenalectomy: A national cancer center database analysis. *J Pediatr Urol* 2021;17(5):735.e1.
- Fassnacht M, Dekkers OM, Else T, Baudin E, Berruti A, de Kraker RR, et al. European Society of Endocrinology Clinical Practice Guidelines on the management of adrenocortical carcinoma in adults, in collaboration with the European Network for the Study of Adrenal Tumors. *Eur J Endocrinol* 2018;179(4):G1–46.
- Fassnacht M, Assie G, Baudin E, Eisenhofer G, de la Fouchardiere C, Haak HR, et al. Adrenocortical carcinomas and malignant pheochromocytomas: ESMO-EURACAN Clinical Practice Guidelines for diagnosis, treatment and follow-up. *Ann Oncol* 2020;31(11):1476–90.
- Gharzai LA, Green MD, Griffith KA, Else T, Mayo CS, Hesseltine E, et al. Adjuvant Radiation Improves Recurrence-Free Survival and Overall Survival in Adrenocortical Carcinoma. *J Clin Endocrinol Metab* 2019;104(9):3743–50.

- [38] Ginsburg KB, Chandra AA, Schober JP, Handorf EA, Uzzo RG, Greenberg RE, et al. Identification of oncological characteristics associated with improved overall survival in patients with adrenocortical carcinoma treated with adjuvant radiation therapy: Insights from the National Cancer Database. *Urol Oncol* 2021;39(11):791.e1.
- [39] Reibetanz J, Rinn B, Kunz AS, Flemming S, Ronchi CL, Kroiss M, et al. Patterns of Lymph Node Recurrence in Adrenocortical Carcinoma: Possible Implications for Primary Surgical Treatment. *Ann Surg Oncol* 2019;26(2):531–8.
- [40] Reibetanz J, Jurowich C, Erdogan I, Nies C, Rayes N, Dralle H, et al. Impact of lymphadenectomy on the oncologic outcome of patients with adrenocortical carcinoma. *Ann Surg* 2012;255(2):363–9.
- [41] Langenhuijsen J, Birtle A, Klatte T, Porpiglia F, Timsit M-O. Surgical Management of Adrenocortical Carcinoma: Impact of Laparoscopic Approach, Lymphadenectomy, and Surgical Volume on Outcomes-A Systematic Review and Meta-analysis of the Current Literature. *Eur Urol Focus* 2016;1(3):241–50.
- [42] Kremer V, et al. Adrenal cortex tumor in childhood, analysis of 20 years. *Pediatr Blood Cancer* 2009;53(5):881.
- [43] Hendricks A, Diers J, Baum P, Weibel S, Kastner C, Müller S, et al. Systematic review and meta-analysis on volume-outcome relationship of abdominal surgical procedures in Germany. *Int J Surg* 2021;86:24–31.
- [44] Diers J, Wagner J, Baum P, Lichthardt S, Kastner C, Matthes N, et al. Nationwide in-hospital mortality following colonic cancer resection according to hospital volume in Germany. *BJS Open* 2019;3(5):672–7.
- [45] Birkmeyer JD, Siewers AE, Finlayson EVA, Stukel TA, Lucas FL, Batista I, et al. Hospital volume and surgical mortality in the United States. *N Engl J Med* 2002;346(15):1128–37.
- [46] Diers J, Baum P, Wagner JC, Matthes H, Pietryga S, Baumann N, et al. Hospital volume following major surgery for gastric cancer determines in-hospital mortality rate and failure to rescue: a nation-wide study based on German billing data (2009–2017). *Gastric Cancer* 2021;24(4):959–69.
- [47] Polat B, Fassnacht M, Pfreundner L, Guckenberger M, Bratengeier K, Johanssen S, et al. Radiotherapy in adrenocortical carcinoma. *Cancer* 2009;115(13):2816–23.
- [48] Wasserman JD, Novokmet A, Eichler-Jonsson C, Ribeiro RC, Rodriguez-Galindo C, Zambetti GP, et al. Prevalence and functional consequence of TP53 mutations in pediatric adrenocortical carcinoma: a children's oncology group study. *J Clin Oncol* 2015;33(6):602–9.
- [49] Mai PL, Best AF, Peters JA, DeCastro RM, Khincha PP, Loud JT, et al. Risks of first and subsequent cancers among TP53 mutation carriers in the National Cancer Institute Li-Fraumeni syndrome cohort. *Cancer* 2016;122(23):3673–81.
- [50] Thariat J, Chevalier F, Orbach D, Ollivier L, Marcy P-Y, Corradini N, et al. Avoidance or adaptation of radiotherapy in patients with cancer with Li-Fraumeni and heritable TP53-related cancer syndromes. *Lancet Oncol* 2021;22(12):e562–74.
- [51] Hendrickson PG, Luo Y, Kohlmann W, Schiffman J, Maese L, Bishop AJ, et al. Radiation therapy and secondary malignancy in Li-Fraumeni syndrome: A hereditary cancer registry study. *Cancer Med* 2020;9(21):7954–63.
- [52] Li Y, et al. Choroid Plexus Carcinomas With TP53 Germline Mutations: Management and Outcome. *Front Oncol* 2021;11:751784.
- [53] Grisanti S, et al. Different management of adrenocortical carcinoma in children compared to adults: is it time to share guidelines? *Endocrine* 2021;74(3):475–7.
- [54] Lalli E, Figueiredo BC. Pediatric adrenocortical tumors: what they can tell us on adrenal development and comparison with adult adrenal tumors. *Front Endocrinol (Lausanne)* 2015;6:23.
- [55] Dehner LP, Hill DA. Adrenal cortical neoplasms in children: why so many carcinomas and yet so many survivors? *Pediatr Dev Pathol* 2009;12(4):284–91.
- [56] Virgone C, Roganovic J, Vorwerk P, Redlich A, Schneider DT, Janic D, et al. Adrenocortical tumours in children and adolescents: The EXPeRT/PARTNER diagnostic and therapeutic recommendations. *Pediatr Blood Cancer* 2021;68(S4):e29025.
- [57] Cecchetto G, Ganarin A, Bien E, Vorwerk P, Bisogno G, Godzinski J, et al. Outcome and prognostic factors in high-risk childhood adrenocortical carcinomas: A report from the European Cooperative Study Group on Pediatric Rare Tumors (EXPeRT). *Pediatr Blood Cancer* 2017;64(6):e26368.
- [58] Fassnacht M, Libé R, Kroiss M, Allolio B. Adrenocortical carcinoma: a clinician's update. *Nat Rev Endocrinol* 2011;7(6):323–35.
- [59] Crona J, Baudin E, Terzolo M, Chrisoulidou A, Angelousi A, Ronchi CL, et al. ENSAT registry-based randomized clinical trials for adrenocortical carcinoma. *Eur J Endocrinol* 2021;184(2). R51–R59.